

# Ultrasonic Total Uncinectomy: A Novel Technique for Complete Anterior Decompression of Cervical Nerve Roots

**Peyman Pakzaban, MD**

Houston MicroNeurosurgery, Houston, Texas

**Correspondence:**

Peyman Pakzaban, MD,  
5388 Lynbrook Dr,  
Houston, TX 77056.  
E-mail: Pakzaban@live.com

**Received,** July 8, 2014.

**Accepted,** August 20, 2014.

**Published Online,** August 29, 2014.

Copyright © 2014 by the  
Congress of Neurological Surgeons.

**BACKGROUND:** In standard anterior cervical discectomy, complete resection of the uncinete process is not commonly attempted because of the risk of injury to the vertebral artery. This may result in incomplete decompression of the nerve root when there is severe osseous foraminal stenosis.

**OBJECTIVE:** To demonstrate the feasibility of total uncinectomy with an ultrasonic bone dissector in patients with concomitant central and foraminal stenosis requiring anterior decompression and fusion.

**METHODS:** A case series of patients with cervical radiculopathy or myeloradiculopathy who underwent single-level or multilevel ultrasonic total uncinectomy (UTU) in combination with anterior cervical discectomy and fusion is presented. The uncinete process was amputated along its base with an ultrasonic bone dissector and removed en bloc to expose the cervical root and the vertebral artery. Data gathered in accordance with routine practice were analyzed retrospectively.

**RESULTS:** Forty-four uncinete processes were resected in 38 patients. No UTU procedures were aborted because of technical difficulties, and no vertebral artery or nerve root injury occurred. Mean follow-up was 28 weeks (range, 14-37 weeks). Mean Neck Disability Index and Visual Analog Scale scores for neck and arm pain improved from 42%, 4.9%, and 6.8% to 23%, 2.6%, and 2.1%, respectively. Postoperative computed tomography and oblique radiographs revealed complete decompression of the neural foramen after UTU.

**CONCLUSION:** UTU is a safe and effective technique for complete decompression of cervical nerve roots when the coexistence of central and foraminal pathology dictates an anterior approach. The surgical technique is described in detail.

**KEY WORDS:** Anterior cervical discectomy, Foraminotomy, Radiculopathy, Ultrasonic surgery, Uncinate process

*Operative Neurosurgery* 10:535–541, 2014

DOI: 10.1227/NEU.0000000000000549



**WHAT IS THIS BOX?**

A QR Code is a matrix barcode readable by QR scanners, mobile phones with cameras, and smartphones. **The QR Code above links to Supplemental Digital Content from this article.**

**A**nterior cervical discectomy and fusion (ACDF) is an effective treatment for central and paracentral anterior compressive pathology producing cervical myelopathy and radiculopathy.<sup>1,2</sup> In ACDF, decompression of the proximal portion of cervical nerve roots

**ABBREVIATIONS:** ACDF, anterior cervical discectomy and fusion; UTU, ultrasonic total uncinectomy

Supplemental digital content is available for this article. Direct URL citations appear in the printed text and are provided in the HTML and PDF versions of this article on the journal's Web site ([www.neurosurgery-online.com](http://www.neurosurgery-online.com)).

may be achieved by partial removal of the medial aspect of the uncinete process, by retrieval of soft herniated disk material from the neural foramen, and indirectly by disk space distraction maintained by an interbody graft. However, when severe osseous foraminal stenosis is present, complete anterior decompression of the cervical nerve root is limited by the risk of injury to the vertebral artery along the lateral aspect of the uncinete process.<sup>3</sup> Furthermore, indirect decompression of the nerve root may be hampered by the inability to distract a degenerated and ankylotic disk space and its neural foramina. In these settings, one could resort to posterior cervical foraminotomy to decompress

the cervical nerve root, but this operation fails to address frequently coexisting anterior pathologies such as disk degeneration, anterior disk osteophytes, and hypertrophic uncovertebral joints. Another option would be a combined anterior-posterior decompression and fusion, which would increase the operative time and the postoperative pain and morbidity.

This report of ultrasonic total uncinectomy (UTU) describes the use of an ultrasonic bone dissector to safely achieve complete resection of the uncinete process during anterior cervical discectomy and to decompress the entire length of the cervical nerve root up to the vertebral artery.

## METHODS

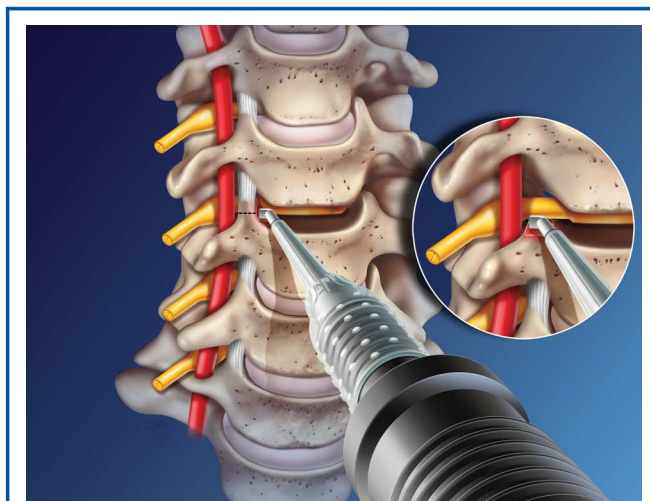
### Patients

Between February and December 2013, patients referred to the author for cervical spondylosis with refractory radiculopathy were selected for UTU in combination with ACDF if they were found to have both severe osseous foraminal stenosis and central stenosis resulting from disk osteophytes. Initial determination of foraminal and central stenosis was made by magnetic resonance imaging and confirmed in all instances with oblique cervical radiographs and, in some cases, with computed tomography (CT). No quantitative assessment of foraminal dimension was performed. Only patients whose level of foraminal stenosis corresponded to their clinical radiculopathy were selected for UTU. In patients with multilevel and bilateral foraminal stenosis, the segments that did not have severe foraminal stenosis or in which stenosis did not correspond to the level and side of the patient's radiculopathy did not receive UTU. Patients completed pain and disability questionnaires preoperatively and postoperatively, were examined at 1 and 6 weeks postoperatively (and as needed thereafter), and underwent dynamic cervical radiographs at 6 weeks and 6 months postoperatively (and as needed thereafter) in accordance with the author's routine practice. In the early cases, some patients had postoperative CT to document the extent of foraminal decompression. Patient records were reviewed retrospectively with respect to operative time, blood loss, length of stay, pain scores, and neurological status.

### Surgical Technique

A standard anterior cervical discectomy was performed at 1 or multiple levels. The posterior osteophytes were drilled away centrally up to the medial aspect of the uncinete process on each side. The posterior longitudinal ligament was resected to expose the dura.

The UTU portion of the operation is illustrated in Figure 1 (also see **Video, Supplemental Digital Content**, <http://links.lww.com/NEU/A686>, which demonstrates a right C5-6 UTU). At the level and side targeted for total uncinectomy, the longus coli muscle was dissected away from the anterolateral surface of the adjacent vertebral bodies and uncinete process such that a Penfield 4 instrument could be gently wedged lateral to the uncinete process (Figure 2A). If the longus coli muscle was especially bulky, a small portion of it was resected just lateral to the disk space. An ultrasonic bone dissector (BoneScalpel, Misonix, Inc) equipped with a microshaver bit was inserted into the disk space under the operating microscope (Figure 1). Ultrasound setting of 10 and irrigation setting of 7 were used. When a particularly hypertrophic uncinete process was encountered, its medial aspect was first shaved down with the ultrasonic microshaver to improve visualization of the lateral extent of the uncinete



**FIGURE 1.** Artist illustration depicting resection of the uncinete process with an ultrasonic bone dissector. After a complete discectomy is performed, the ultrasonic bone dissector is used to amputate the base of the uncinete process along the dashed line. Inset, complete decompression of the cervical nerve root up to the vertebral artery after removal of the uncinete process. Illustration provided courtesy of Misonix, Inc.

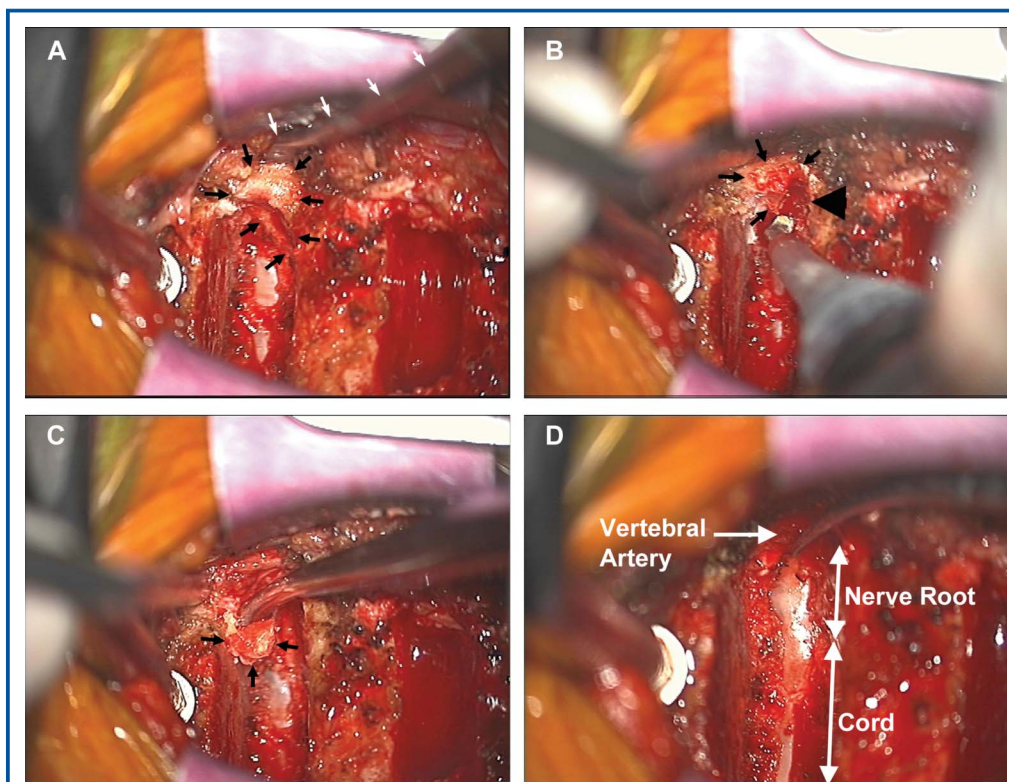
process. Then, the shaving surface of the microshaver was directed laterally, and the base of the uncinete process was amputated flush with the superior endplate (Figure 1, inset, and Figure 2B). In this step, the microshaver was moved in repeated brushstrokes in a posterior-to-anterior direction, originating at the depth of the uncinete process where the blunt tip of the microshaver was allowed to come in brief contact with the nerve root and the lateral epidural veins. After the lateral cortical margin of the uncinete process consistently became mobile. Then a Penfield 4 instrument passed lateral to the uncinete process was used to fold the uncinete process into the disk space. At this stage, the tip of the uncinete process remained attached to the upper vertebral body via the uncovertebral ligaments. The Penfield 4 was replaced with a 2-0 curette to detach these ligaments and to mobilize the uncinete process medially and remove it (Figure 2C). If bleeding was encountered from the venous plexus surrounding the vertebral artery, it was readily controlled with Gelfoam and occasional microbipolar electrocautery. The soft tissues overlying the nerve root were incised with a 1-mm Kerrison rongeur or a microhook to fully expose the nerve root all the way to the medial margin of the vertebral artery (Figure 2D).

Fusion with iliac crest allograft and plating with Synthes CSLP plate (DePuy Synthes Companies) were performed in standard fashion. All patients were observed in the hospital overnight and discharged within 24 hours. All patients wore a soft cervical collar for 1 month postoperatively.

## RESULTS

### Patient Population

Thirty-eight patients underwent single-level or multilevel ACDF in combination with single-level or multi-level UTU by a single surgeon during the study period. In total, 66 disks were



**FIGURE 2.** Intraoperative photographs demonstrating the surgical steps of a left C4-5 ultrasonic total uncinectomy. Cranial direction is to the left. **A**, after complete resection of the disk and dissection of longus coli muscle, the margins of the unciniate process are visualized (small black arrows). A Penfield 4 instrument is shown wedged lateral to the unciniate process (small white arrows), retracting the longus coli. **B**, the microshaver bit is directed laterally to amputate the base of the unciniate process (black arrowhead). **C**, the mobilized unciniate process is folded in medially. **D**, after removal of the unciniate process, the extent of nerve root exposure and the location of vertebral artery are shown.

removed in combination with 44 unciniate processes, as broken down in Table 1. No bilateral uncinectomies were performed. Six patients had 2-level UTUs when there was radiographic evidence of severe foraminal stenosis at 2 adjacent levels and the patients had symptoms that either spanned 2 different nerve roots or could not be definitively attributed to a single nerve root. The baseline demographic and clinical data are presented in Table 2. The patients' mean age was 65 years (range, 43-80 years). There

were 17 men and 21 women. All patients had neck pain and a significant cervical radiculopathy. Fifteen patients (40%) had arm weakness (including 3 with complete deltoid paralysis), and 6 patients (16%) had a superimposed myelopathy. One-level uncinectomies were performed with relatively equal frequency at C4-5 (10 patients), C5-6 (12 patients), and C6-7 (10 patients). Six additional patients had 2-level uncinectomies. The mean  $\pm$  SD preoperative Neck Disability Index was  $42 \pm 9\%$ . The mean preoperative Visual Analog Scale (VAS) scores for neck pain and arm pain were  $4.9 \pm 2.0$  and  $6.8 \pm 2.4$ , respectively.

**TABLE 1. Breakdown of Number of Patients Who Received Anterior Cervical Discectomy and Fusion Combined With Ultrasonic Total Uncinectomy<sup>a</sup>**

	1-Level UTU, n	2-Level UTU, n	3-Level UTU, n
1-Level ACDF	17		
2-Level ACDF	13	5	
3-Level ACDF	2	1	0

<sup>a</sup>ACDF, anterior cervical discectomy and fusion; UTU, ultrasonic total uncinectomy.

**Perioperative Results**

All planned uncinectomies were performed without intraoperative complications and without the need to abort or modify the surgical plan. There were no instances of vertebral artery injury. The perioperative results are summarized in Table 3. Blood loss and operative time increased in proportion to the number of ACDF and UTU levels. Mean estimated blood loss ranged from 48.5 mL in 1-level ACDF/UTA cases to 150 mL in 3-level ACDF with 2-level UTU. Mean operative time ranged from

**TABLE 2. Baseline Demographic and Clinical Data<sup>a</sup>**

Age, y	64.8 ± 8.2 <sup>b</sup>
Male/female, n	17/21
Presentation, n (%)	
Neck pain	38 (100)
Radiculopathy	38 (100)
Radiculopathy with arm weakness	15 (40)
Myelopathy	6 (16)
Foraminal stenosis/UTU level, n	
C4-5	10
C5-6	12
C6-7	10
C4-5 and C5-6	4
C5-6 and C6-7	2
Preoperative Neck Disability Index, %	42 ± 9 <sup>b</sup>
Preoperative VAS score for neck pain	4.9 ± 2.0 <sup>b</sup>
Preoperative VAS score for arm pain	6.8 ± 2.4 <sup>b</sup>

<sup>a</sup>UTU, ultrasonic total uncinectomy; VAS, Visual Analog Scale.

<sup>b</sup>Mean ± SD.

58.2 minutes for 1-level ACDF/UTU cases to 142 minutes in 3-level ACDF with 2-level UTU. All patients were successfully discharged home within 24 hours.

### Clinical and Radiographic Outcome

Mean follow-up was 28 ± 7 weeks (range, 14-37 weeks). Mean improvement in VAS scores for neck pain and arm pain between preoperative and final postoperative encounters was 2.3 ± 1.2 and 4.7 ± 2.3, respectively. Mean improvement in Neck Disability Index was 19 ± 7.1%. There were no instances of neurological worsening after surgery. Of the 13 patients with incomplete arm weakness, 11 had recovered normal motor strength by 6 weeks postoperatively, and the other 2 had achieved

**TABLE 3. Perioperative Results<sup>a</sup>**

	n	Blood Loss, mL <sup>b</sup>	Surgery Time, min <sup>b</sup>	Length of Stay <24 h, %
<b>1-Level ACDF with</b>				
1-Level UTU	17	49 ± 21	58 ± 6	100
<b>2-Level ACDF with</b>				
1-Level UTU	13	81 ± 22	73 ± 7	100
2-Level UTU	5	104 ± 21	91 ± 8	100
<b>3-Level ACDF with</b>				
1-Level UTU	2	125 ± 35	121 ± 16	100
2-Level UTU	1	150	142	100

<sup>a</sup>ACDF, anterior cervical discectomy and fusion; UTU, ultrasonic total uncinectomy.

<sup>b</sup>Results expressed as mean ± standard deviation.

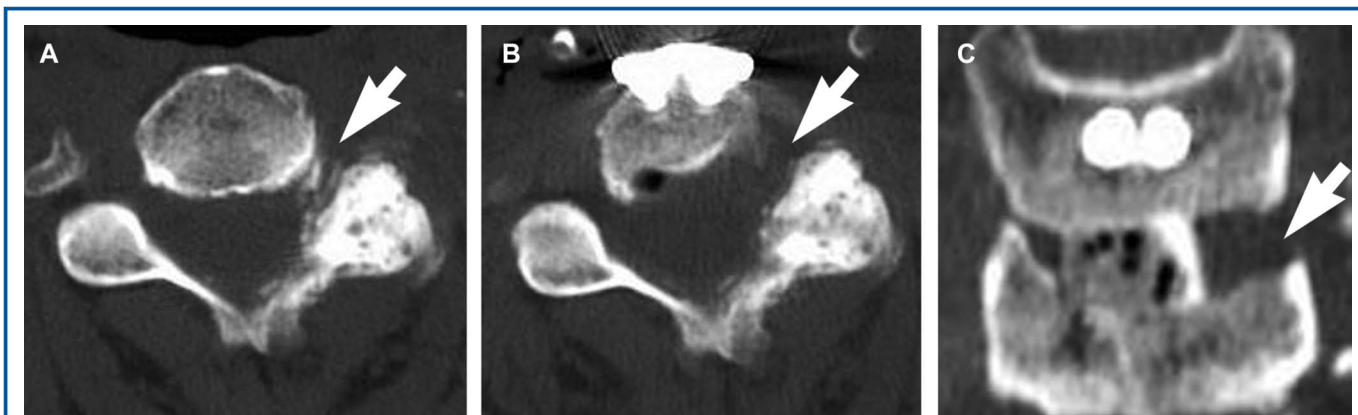
normal strength by the 6-month follow-up. The 3 patients with complete deltoid paralysis had return of antigravity strength or better by 6 months postoperatively. All 6 patients with myelopathy exhibited significant improvements in gait, tone, and hand dexterity by 6 weeks postoperatively and had no significant evidence of myelopathy (other than residual hyperreflexia) by 6 months postoperatively.

Postoperative CT performed in a few patients early in the surgical series revealed readily appreciable improvements in the dimensions of the target neural foramen. Representative CT data from a patient with left deltoid paralysis are presented in Figure 3. The preoperative image (Figure 3A) reveals severe left C4-5 osseous foraminal stenosis resulting from uncovertebral and facet hypertrophy. The postoperative axial image (Figure 3B) reveals substantial widening of the left neural foramen and spinal canal. The postoperative coronal image (Figure 3C) reveals complete resection of the left uncinete process. All patients had oblique radiographs to assess the patency of the target neural foramen at the time of routine postoperative dynamic lateral radiographs. A representative example is shown in Figure 4. The hypertrophic uncinete process is seen narrowing the C6 neural foramen preoperatively (Figure 4A). The expanded neural foramen after UTU is seen on the postoperative radiograph (Figure 4B).

In accordance with our routine clinical practice, solid fusion was defined as the presence of bridging bone between the endplates on lateral radiographs and a change in the interspinous distance of ≤2 mm. The term satisfactory progress toward fusion was used to label asymptomatic patients who at 1 to 6 months of follow-up had remaining radiolucent lines or a change in the interspinous distance of 2 to 4 mm with no evidence of hardware loosening or graft resorption. Within the limited follow-up period of this study, 17 patients had solid fusion, and the remaining 21 patients had satisfactory progress toward fusion. Of the 17 patients with solid fusion, 6 had satisfactory progress toward fusion at 6 months and went on to develop solid fusion at 9 to 12 months. No patients developed hardware failure, resorption of the bone graft, or gross instability within the follow-up period.

### Complications

The complications are presented in Table 4. There were no instances of vertebral artery injury, neck hematoma, or airway compromise. One patient had wound erythema successfully treated with oral antibiotics. There were no cases of deep wound infection or purulence. Three patients experienced mild transient hoarseness that resolved by 6 weeks after surgery. There were no cases of recurrent laryngeal nerve palsy. Two patients had persistent mild to moderate dysphagia 6 weeks after surgery that resolved without intervention by 3 months after surgery. There were no cases with worsening neurological deficit, graft displacement, or hardware failure. No patients developed Horner syndrome (assessed by evaluation of ptosis and pupil size discrepancy in a darkened room at 1 and 6 weeks postoperatively). No patient experienced major systemic complications



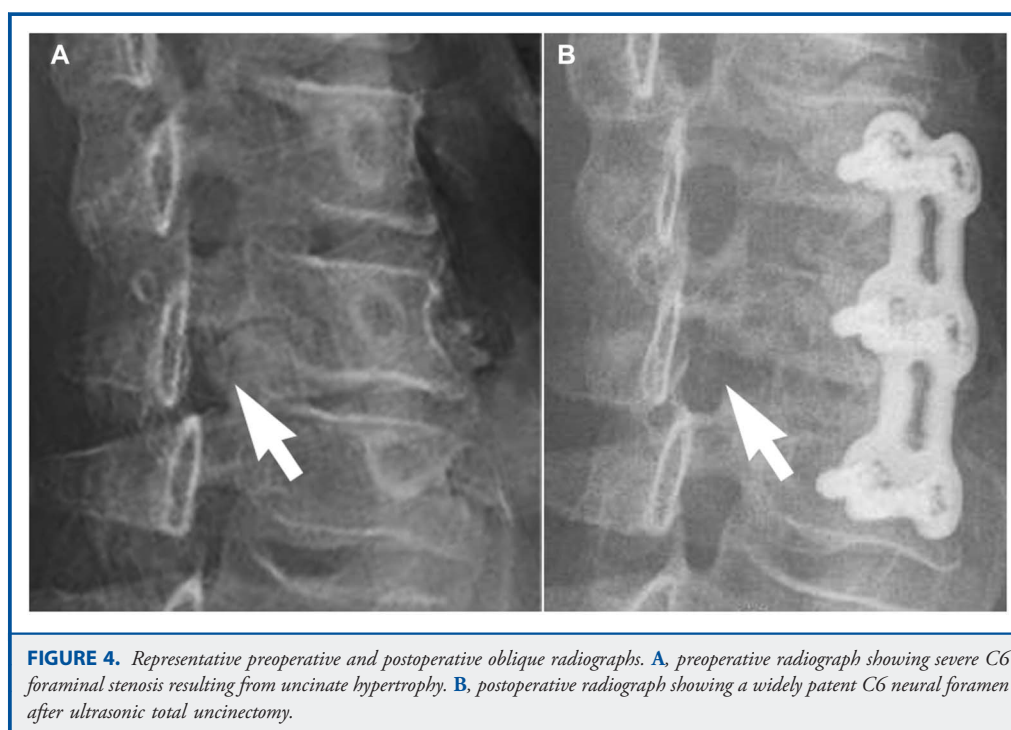
**FIGURE 3.** Representative preoperative and postoperative computed tomography (CT) images. **A**, preoperative axial CT image showing severe left C4-5 osseous foraminal stenosis in a patient with deltoid paralysis. **B**, postoperative axial CT image showing substantial widening of the left neural foramen. **C**, postoperative coronal CT images showing complete resection of the left uncinete process.

such as myocardial infarction or pulmonary embolism in the postoperative period.

## DISCUSSION

The mechanism of ultrasonic bone ablation has been described in detail elsewhere.<sup>4</sup> This mechanism confers a relative selectivity to ultrasonic bone dissectors such that dense bone tissue is destroyed before and in preference to soft tissues (eg, dura and

arterial wall), thus permitting safe bone removal adjacent to important soft tissue structures.<sup>4-7</sup> Moreover, the absence of a high-speed spinning burr in ultrasonic bone dissectors eliminates the possibility of unwanted soft tissue capture/injury and erratic drill movements. Finally, the microshaver bit of the ultrasonic bone disector has a side-cutting surface (Figure 1), which makes it possible for the blunt tip and smooth back of the bit to come in brief contact with the nerve roots and vertebral artery without risk of injury, as demonstrated in this report.



**FIGURE 4.** Representative preoperative and postoperative oblique radiographs. **A**, preoperative radiograph showing severe C6 foraminal stenosis resulting from uncinete hypertrophy. **B**, postoperative radiograph showing a widely patent C6 neural foramen after ultrasonic total uncinectomy.

**TABLE 4. Complications**

Complication	n
Vertebral artery injury	0
Dural laceration	0
Neck hematoma with airway compromise	0
Wound erythema	1
Wound infection/purulence	0
Transient hoarseness, mild	3
Recurrent laryngeal nerve palsy	0
Dysphagia after 6 wk	2
Worsening neurological deficit	0
Graft or hardware displacement or failure	0
Horner syndrome	0
Major systemic complications	0

In his initial description of anterior cervical foraminotomy, Jho<sup>8-10</sup> demonstrated the technique for complete resection of the uncinat process with a drill. Since then, others have modified this demanding technique to generally avoid drilling of the lateral margin of the uncinat process to lessen the risk of injury to the vertebral artery.<sup>11-20</sup> In all of these reports, the goal has been to preserve the disk space and to avoid a fusion, which by necessity limits visualization and access to the uncinat process.<sup>8-22</sup> Despite the aforementioned modifications, the technique for standalone anterior cervical foraminotomy remains challenging and carries a significant risk of complications in inexperienced hands.<sup>22</sup> Anatomical morphometric analysis has revealed the distance between the vertebral artery and the lateral margin of the uncinat process to be 1.7 to 2.8 mm, leaving little margin for error.<sup>3</sup> Furthermore, a high reoperation rate has been reported after standalone anterior cervical foraminotomy, possibly related to the importance of uncovertebral joints in preserving stability.<sup>21</sup>

The technique presented in this report differs from the previously described anterior cervical foraminotomy operations in 3 important aspects. First, a complete anterior discectomy is performed that permits superior visualization of the uncinat process through the disk space. Second, complete en bloc resection of the uncinat process is carried out with the aid of an ultrasonic bone dissector, which substantially diminishes the risk of injury to the vertebral artery and provides a smoother and more controlled surgical experience. Third, a fusion is performed to overcome any instability produced by total uncinectomy and discectomy.

We experienced no instances of vertebral artery injury or nerve root injury in this study. Minor complications were similar to those experienced with standard ACDF. Although no direct comparison was performed, we estimate that the blood loss was marginally (but not prohibitively) higher than with standard ACDF. As expected, bleeding can occur from lateral epidural veins and the paravertebral venous plexus after removal of the uncinat process, but it requires no special intervention other than gentle compression with Gelfoam. Similarly, the surgery duration was

not prohibitively prolonged (Table 3). Each UTU level adds an estimated  $\approx$  15 minutes to surgery time. Unlike standalone anterior cervical foraminotomy, the surgical technique is straightforward and easily within reach of surgeons experienced in ACDF.

Excellent clinical outcomes were achieved with ACDF plus UTU, similar to what one expects with standard ACDF. The follow-up period in this study is too short to make any definitive statements about fusion; however, no pattern that would raise concern for gross instability or increased pseudarthrosis compared with standard ACDF was encountered. Whether there is a difference between fusion rates in ACDF with UTU and ACDF without UTU is a question that would have to be addressed by a future prospective study. It is also important to note that this was a selected group of patients who had severe foraminal stenosis not accessible by the standard ACDF approach. Whether complete resection of uncinat process will actually improve clinical outcome in patients with severe osseous foraminal stenosis is another issue that would have to be assessed in a controlled trial. The purpose of this study was to establish the feasibility and safety of UTU and to add another surgical option to the spine surgeon's armamentarium when faced with concomitant central and foraminal stenosis. Finally, demonstration of UTU by experienced surgeons to surgical trainees would allow the latter to fully appreciate the surgical anatomy of the uncinat process and its relationship to the vertebral artery, thus improving their confidence and efficiency when performing a standard ACDF.

## CONCLUSION

UTU is a safe, novel technique for complete decompression of cervical nerve roots through an anterior approach. The technique may be used when severe osseous foraminal stenosis accompanies other pathologies that require an anterior approach to the cervical spine.

## Disclosure

The author has served as a research consultant for Misonix, Inc. No financial support was received for this study from Misonix, Inc or any other entity.

## REFERENCES

- Hermansen A, Hedlund R, Vavruch L, Peolsson A. Positive predictive factors and subgroup analysis of clinically relevant improvement after anterior cervical decompression and fusion for cervical disc disease: a 10- to 13-year follow-up of a prospective randomized study: clinical article. *J Neurosurg Spine*. 2013;19(4):403-411.
- Matz PG, Holly LT, Groff MW, et al. Indications for anterior cervical decompression for the treatment of cervical degenerative radiculopathy. *J Neurosurg Spine*. 2009;11(2):174-182.
- Kim SH, Lee JH, Kim JH, Chun KS, Doh JW, Chang JC. Anatomical morphometric study of the cervical uncinat process and surrounding structures. *J Korean Neurosurg Soc*. 2012;52(4):300-305.
- Pakzaban P. *BoneScalpel Ultrasonic Bone Dissector: Applications in Spine Surgery and Surgical Technique Guide*. Farmingdale, NY: Misonix; 2014. <https://itunes.apple.com/us/book/bonescalpel-ultrasonic-bone/id870326568>. Accessed April 30, 2014.

5. Bydon M, Xu R, Papademetriou K, et al. Safety of spinal decompression using an ultrasonic bone curette compared with a high-speed drill: outcomes in 337 patients. *J Neurosurg Spine*. 2013;18(6):627-633.
6. Hu X, Ohnmeiss DD, Lieberman IH. Use of an ultrasonic osteotome device in spine surgery: experience from the first 128 patients. *Eur Spine J*. 2013;22(12):2845-2849.
7. Parker SL, Kretzer RM, Recinos PF, et al. Ultrasonic BoneScalpel for osteoplastic laminoplasty in the resection of intradural spinal pathology: case series and technical note. *Neurosurgery*. 2013;73(1 suppl operative):ons61-ons66.
8. Jho HD. Microsurgical anterior cervical foraminotomy for radiculopathy: a new approach to cervical disc herniation. *J Neurosurg*. 1996;84(2):155-160.
9. Jho HD. Spinal cord decompression via microsurgical anterior foraminotomy for spondylotic cervical myelopathy. *Minim Invasive Neurosurg*. 1997;40(4):124-129.
10. Jho HD. Decompression via microsurgical anterior foraminotomy for cervical spondylotic myelopathy: technical note. *J Neurosurg*. 1997;86(2):297-302.
11. Choi G, Arbatti NJ, Modi HN, et al. Transcorporeal tunnel approach for unilateral cervical radiculopathy: a 2-year follow-up review and results. *Minim Invasive Neurosurg*. 2010;53(3):127-131.
12. Choi G, Lee SH, Bhanot A, Chae YS, Jung B, Lee S. Modified transcorporeal anterior cervical microforaminotomy for cervical radiculopathy: a technical note and early results. *Eur Spine J*. 2007;16(9):1387-1393.
13. Koc RK, Menkü A, Tucer B, Göçmez C, Akdemir H. Anterior cervical foraminotomy for unilateral spondylotic radiculopathy. *Minim Invasive Neurosurg*. 2004;47(3):186-189.
14. Lee JY, Lohr M, Impekoven P, et al. Small keyhole transuncal foraminotomy for unilateral cervical radiculopathy. *Acta Neurochir (Wien)*. 2006;148(9):951-958.
15. Park YK, Moon HJ, Kwon TH, Kim JH. Long-term outcomes following anterior foraminotomy for one- or two-level cervical radiculopathy. *Eur Spine J*. 2013;22(7):1489-1496.
16. Pechlivanis I, Brenke C, Scholz M, Engelhardt M, Harders A, Schmieder K. Treatment of degenerative cervical disc disease with uncoforaminotomy: intermediate clinical outcome. *Minim Invasive Neurosurg*. 2008;51(4):211-217.
17. Saringer W, Nöbauer I, Reddy M, Tschabitscher M, Horaczek A. Microsurgical anterior cervical foraminotomy (uncoforaminotomy) for unilateral radiculopathy: clinical results of a new technique. *Acta Neurochir (Wien)*. 2002;144(7):685-694.
18. Saringer WF, Reddy B, Nöbauer-Huhmann I, et al. Endoscopic anterior cervical foraminotomy for unilateral radiculopathy: anatomical morphometric analysis and preliminary clinical experience. *J Neurosurg*. 2003;98(2 suppl):171-180.
19. Takeuchi M, Takayasu M, Yasuda M, et al. Transvertebral anterior key hole foraminotomy without fusion for the cervicothoracic junction. *Acta Neurochir (Wien)*. 2012;154(10):1797-1802.
20. Umabayashi D, Hara M, Nakajima Y, Nishimura Y, Wakabayashi T. Transvertebral anterior cervical foraminotomy: midterm outcomes of clinical and radiological assessments including the finite element method. *Eur Spine J*. 2013;22(12):2884-2890.
21. Hacker RJ, Miller CG. Failed anterior cervical foraminotomy. *J Neurosurg*. 2003;98(2 suppl):126-130.
22. Jho HD. Failed anterior cervical foraminotomy. *J Neurosurg*. 2003;98(2 suppl):121-125; discussion 125.

---

*Supplemental digital content is available for this article. Direct URL citations appear in the printed text and are provided in the HTML and PDF versions of this article on the journal's Web site (www.neurosurgery-online.com).*

---

## COMMENT

In this article, the author describes a unique way of removing the uncinatate process that contributes to radiculopathy using an ultrasonic bone dissector. Ultrasonic bone dissectors have been used in various neurosurgical interventions. The author nicely demonstrates this technique to remove the uncinatate process.

Nevertheless, as the author mentions, the standard technique of removing the uncinatate process and distracting the interspace opens up the foramen nicely, as many clinical studies have shown. However, in those cases in which the uncinatate process is very prominent, this elegant technique could be very useful.

**Volker K. Sonntag**  
Phoenix, Arizona